

## REVIEW

# Work-up of the solitary pulmonary nodule

Leslie Eisenbud Quint

Department of Radiology, University of Michigan Health Center, 1500 East Medical Center Dr., Ann Arbor, MI, USA

Corresponding address: Professor L E Quint, Department of Radiology, University of Michigan Health Center, 1500 East Medical Center Dr., Ann Arbor, MI 48109-0030, USA. E-mail: lequint@umich.edu

Date accepted for publication 5 November 2002

### Abstract

Although the solitary pulmonary nodule (SPN) is a common presentation of lung cancer, most SPNs are benign. The challenge in evaluating SPNs is to avoid invasive procedures in patients who have benign nodules, without allowing potentially curable bronchogenic carcinomas the time to progress to more advanced or even unresectable disease. Various approaches include assessment of nodule morphology, interval growth and contrast enhancement, as well as techniques such as percutaneous biopsy, positron emission tomography scanning and depreotide imaging. The role of each of these approaches is discussed.

**Keywords:** Lung neoplasms; diagnostic methods.

### Introduction

Although the solitary pulmonary nodule (SPN) is a common presentation of lung cancer, most SPNs are benign. The challenge in evaluating SPNs is to avoid invasive procedures in patients who have benign nodules without allowing potentially curable bronchogenic carcinomas the time to progress to more advanced or even unresectable disease. Whereas calcification is the single best morphologic indicator of benignancy, behavior (i.e. lack of growth) is far better than any morphologic criterion at predicting benignancy. Any predictor of benignancy must err on the side of intervention—it is better to resect a benign SPN unnecessarily than erroneously to call a malignant SPN benign.

### Calcification

At the current time, most patients with a non-calcified SPN at chest radiography and no comparison films go to CT. Thin-section CT facilitates the detection of calcification that could be missed on chest radiographs;

the thickness of the sections used should be no larger than half the diameter of the nodule, in order to avoid partial volume averaging with adjacent lung tissue, and all images should be obtained during a single breath hold, in order to eliminate scan plane mis-registration. Although CT densitometry using a reference phantom (a cylinder filled with a calcium-containing substance that serves as a standard of comparison to assess density of a patient's nodule) has been helpful in the past, improvements in scanner technology have made use of the phantom largely unnecessary; in current practice it is rarely, if ever, used. If calcification is identified, the pattern of calcification should be considered when evaluating a nodule. Granulomas typically show diffuse or near-complete calcification or a central nidus of calcification. The finding of multiple large, scattered calcifications in a 'popcorn' pattern is highly suggestive of a hamartoma; the diagnosis is confirmed if portions of the nodule show fatty attenuation, with or without associated calcification (Fig. 1). It should be remembered that not all calcifications are benign: carcinomas may occasionally show stippled and/or eccentric calcification.

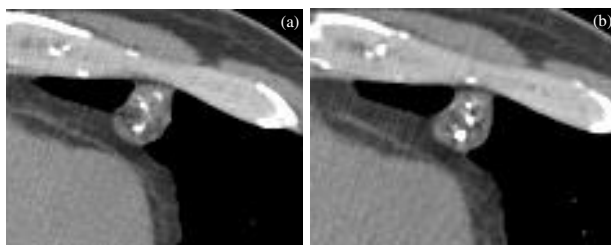
This paper is available online at <http://www.cancerimaging.org>. In the event of a change in the URL address, please use the DOI provided to locate the paper.

## Contrast enhancement

Preliminary studies with follow-up of non-calcified SPNs have reported that all, or nearly all, malignant SPNs enhance by at least 20 Hounsfield units (HU) within 2–4 min after contrast injection; few benign SPNs enhance to that degree. Based on these promising preliminary results, a multi-center study subsequently evaluated 356 SPNs that were 5–40 mm, solid, relatively spherical, homogeneous and without calcification or fat on non-contrast images. Contrast-enhanced images were obtained at 1–4 min after onset of injection (3 mm collimation, 420 mgI/kg, 300 mgI/ml administered at 2 ml/s). CT showed 98% sensitivity, 58% specificity and 77% accuracy in diagnosing malignancy, using a threshold of 15 HU<sup>[1]</sup>. Prevalence of malignancy in this patient group was 48% (171/356 nodules). Using this technique, false-negative exams may occur occasionally in necrotic or mucin-producing tumors. The authors suggest using the lung nodule enhancement technique in lesions that are  $\leq 2$  cm in diameter; lesions of this size are less likely to be necrotic, are more likely to be benign, and are often difficult to percutaneously biopsy. The low specificity (high false-positive rate) may be explained by an additional study that demonstrated overlap in enhancement of malignant lesions and benign lesions with active inflammation<sup>[2]</sup>. Perhaps because of the low specificity, this technique currently plays a minor role in the work-up of the SPN at most institutions.

## CT follow-up imaging

If a patient and physician opt to follow a nodule using CT, then a high-quality baseline study should be obtained using 1–1.25 mm thick sections. Therefore, if a nodule is initially detected on a low-dose lung cancer screening CT, or other CT performed using relatively thick sections, the patient should be brought back for a standard dose, thin-section, diagnostic CT. All subsequent studies should be performed using the same techniques, to allow optimal comparison. Follow-up CT imaging may be performed at 3-month intervals for the first year, and at 6-month intervals for the second year.



**Figure 1** Benign calcification. Lung nodule shows fat and calcium in a 'popcorn' pattern, consistent with a hamartoma.

Two preliminary studies that looked at nodule phantoms and real patient nodules found that thin-section CT

could enable detection of very minute changes in lung nodule cross-sectional areas and volumes<sup>[3]</sup>. Volume assessment appeared to be superior to cross-sectional area assessment due to the potential for asymmetric growth, particularly in the cranio-caudal direction. An important aspect of these studies was the use of automatic segmentation for lesion boundary definition, thus eliminating observer bias and other sources of manual edge determination. The authors concluded that repeat CT at 30 days can detect growth for most neoplasms that are at least 5 mm in diameter, assuming typical doubling times of  $\leq 180$  days. This observation has very important implications for the work-up of a lung nodule, with the potential to obviate many other invasive and/or expensive procedures. However, this technique will not be ready for routine clinical use until it is confirmed in other, larger studies and until automatic segmentation becomes widely available. In fact, other authors have found that a large proportion of tumors have much longer doubling times ( $\geq 465$  days), and therefore short-term follow-up may not be helpful<sup>[4]</sup>.

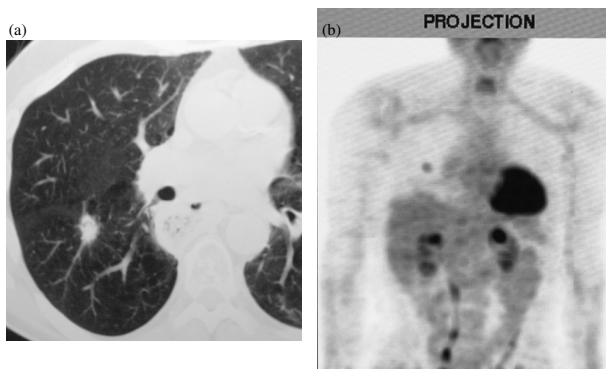
## Percutaneous biopsy

In some centers, nodules that are indeterminate at CT densitometry may be percutaneously biopsied; high accuracies have been reported, with a positive predictive value of 99%. The real challenge, of course, is to make a negative biopsy accurate and furthermore to establish a specific benign diagnosis. Using systematic staining and culture schemes, high negative predictive values have been reported for patients in whom a specific benign diagnosis could be made. However, the negative predictive value is generally lower in patients with a biopsy showing non-specific inflammation. Recently published studies have reported overall negative predictive values ranging from 52 to 84%<sup>[5]</sup>.

In a patient with a high pre-test probability of harboring lung cancer, a positive percutaneous biopsy will lead to thoracotomy. On the other hand, a non-specific negative biopsy in such a patient may not be sufficiently reliable due to sampling error, and many surgeons will resect the nodule regardless of the biopsy results. Therefore, preoperative biopsy is generally not indicated in patients with a high probability of malignancy<sup>[6]</sup>. An exception would occur in the patient with a history of previous extrathoracic primary neoplasm. At some institutions, it is advocated that a non-specific negative percutaneous biopsy of an SPN be followed by a repeat biopsy. If the repeat biopsy is also negative for neoplasm, then close follow-up is advised. Some investigators have suggested the use of core or cutting needle biopsies to increase the yield of specific benign diagnoses<sup>[7]</sup>; unfortunately such biopsies do not appear to change the overall false-negative rate compared to fine-needle aspiration biopsy (generally approximately 15–25%). Thus, a non-specific negative biopsy result should be viewed with caution.

### Positron emission tomography (PET)

The ability of FDG–PET to separate malignant from benign lesions is high (accuracy approximately 90%), but not totally perfect (Fig. 2)<sup>[8,9]</sup>. Nodules less than 8 mm in diameter may be particularly difficult to evaluate because of their small size relative to the resolution of the PET scanner. High tracer uptake can sometimes be seen in an inflammatory or infectious process, such as aspergillosis or TB. False-negative scans sometimes occur in patients with bronchioloalveolar cell carcinoma and carcinoids, tumors that have considerably lower uptake of FDG than other lung cancers. With a prevalence of 4–10% false-negatives, there are risks of missing tumors if PET is the only test performed. Most investigators would recommend follow-up imaging tests of SPNs following a negative PET to exclude tumor growth, as a small percentage of patients with negative PET scans of SPN will have malignant tumors present. At many centers, PET is carried out in the more clinically challenging cases, such as the difficult-to-biopsy lesions (e.g. patients with severe emphysema), or in patients who are at greater than usual risk at surgical assessment/biopsy.



**Figure 2** New, primary bronchogenic carcinoma in a patient who has undergone previous esophagectomy and gastric pull-through for esophageal carcinoma. CT (a) shows an SPN that is FDG avid at PET (b).

### Depreotide imaging

Initial studies have been done using a relatively new metabolic imaging agent, Tc 99m-depreotide, for distinguishing benign from malignant pulmonary nodules<sup>[10]</sup>. A multi-center study involving 114 patients found 97% sensitivity and 73% specificity in diagnosing lung cancer. Thus this imaging technique is promising, particularly for use in centers without access to a PET scanner.

### Conclusion

Distinguishing between benign and malignant SPNs is an area of active, ongoing research. Various approaches may be considered, depending upon patient circumstances and available technology.

### Key points

- Thin-section CT facilitates the detection of calcification and the assessment of a benign vs. a malignant pattern of calcification.
- A non-specific, negative percutaneous biopsy should be viewed with caution, as it does not necessarily exclude malignancy.
- The ability of FDG–PET to separate malignant from benign SPNs is high (accuracy approximately 90%), but not totally perfect.

### References

- [1] Swensen SJ, Viggiano RW, Midthun DE *et al.* Lung nodule enhancement at CT: multi-center study. *Radiology* 2000; 214: 73–80.
- [2] Zhang M, Kono M. Solitary pulmonary nodules: evaluation of blood flow patterns with dynamic CT. *Radiology* 1997; 205: 471.
- [3] Yankelevitz DF, Reeves AP, Kostis WJ, Zhao B, Henschke CI. Small pulmonary nodules: volumetrically determined growth rates based on CT evaluation. *Radiology* 2000; 217: 251–6.
- [4] Winer-Muram HT, Jennings SG, Tarver RD *et al.* Volumetric growth rate of stage I lung cancer prior to treatment: serial CT scanning. *Radiology* 2002; 223: 798–805.
- [5] Klein J, Zarka M. Transthoracic needle biopsy: an overview. *J Thorac Imaging* 1997; 12: 232–49.
- [6] Yankelevitz DF, Wisnivesky JP, Henschke CI. Comparison of biopsy techniques in assessment of solitary pulmonary nodules. *Semin Ultrasound, CT MR* 2000; 21: 139–48.
- [7] Lucidarme O, Howarth N, Finet JF, Grenier PA. Intrapulmonary lesions: percutaneous automated biopsy with a detachable, 18-gauge, coaxial cutting needle. *Radiology* 1998; 207: 759–65.
- [8] Lowe V, Fletcher J, Gobar L *et al.* Prospective investigation of positron emission tomography in lung nodules. *J Clin Oncol* 1998; 16: 1075–84.
- [9] Prauer HW, Weber WA, Romer W, Treumann T, Ziegler SI, Schwaiger M. Controlled prospective study of positron emission tomography using the glucose analogue [18F]fluorodeoxyglucose in the evaluation of pulmonary nodules. *Br J Surg* 1998; 85: 1506–11.
- [10] Blum J, Handmaker H, Lister-James J, Rinne N. A multi-center trial with a somatostatin analog (99m)Tc depreotide in the evaluation of solitary pulmonary nodules. *Chest* 2000; 117: 1232–8.