

CT/MRI of nodal metastases in pelvic cancer

Janet E Husband

Academic Department of Diagnostic Radiology, The Royal Marsden NHS Trust, Sutton, Surrey, UK

Corresponding address: J E Husband, Academic Department of Diagnostic Radiology, The Royal Marsden NHS Trust, Downs Road, Sutton, Surrey SM2 5PT, UK

Date accepted for publication 30 January 2002

Keywords: CT, MRI, nodal metastases, pelvic cancer.

Introduction

The accurate detection of lymph node metastases is one of the most important challenges in cancer imaging today, for the presence of nodal disease is a powerful adverse prognostic indicator. Pre-treatment detection of malignant nodes determines patient management, frequently distinguishing surgical candidates from those best suited to non-surgical therapy. However, the results of CT and MR imaging have been disappointing with poor sensitivities and specificities, low sensitivities being due to the inability to identify metastases in normal-sized nodes or those that are only minimally enlarged, and poor specificities resulting from nodal enlargement due to benign pathology. MR lymphography can demonstrate small nodal deposits, but the technique remains in the research arena, requires high-resolution thin sections to produce good image quality and is expensive. It is therefore likely to be used, at least for the foreseeable future, in highly selected patient groups. In order to give appropriate consideration to the likelihood of a prominent or enlarged lymph node harbouring a metastasis, it is incumbent on the radiologist to use all the relevant information available. This frequently requires discussion with clinicians or review of the patient's case notes.

In order to provide the best possible assessment of nodal status with CT and MR, the radiologist requires detailed knowledge of: (1) the primary tumour in terms of the patterns of spread and the incidence of nodal metastases at different stages of disease; (2) the characteristic CT/MR features of nodal involvement; (3) the pitfalls in diagnosis of nodal disease; (4) the accuracy of imaging and the impact of positive and negative results on patient management.

The radiologist also needs information on the patient's current therapy and previous treatment, as such knowledge may influence interpretation. For example, a patient who has previously been treated with pelvic radiotherapy is more likely to relapse in nodes outside the radiotherapy field, thus the development of nodal enlargement in the pelvis should be interpreted with caution. It is also important to know whether the patient has any coincidental disease that could be a cause of nodal enlargement.

The primary tumour: patterns of lymphatic spread and incidence of nodal involvement

In most pelvic cancers the incidence of nodal involvement increases with primary tumour stage and is also related to histological tumour grade and tumour bulk. The recurrence rate and overall survival are directly related to nodal spread.

Prostate cancer

Prostate cancer spreads via lymphatics in the neurovascular bundles to the obturator, presacral, hypogastric and external iliac nodes (Fig. 1). Further spread is to the common iliac and paraaortic nodes^[1].

External iliac nodes are involved in 60% and obturator nodes in over 50% of node positive cases (Fig. 2)^[1].

This paper is available online at <http://www.cancerimaging.org>. In the event of a change in the URL address, please use the DOI provided to locate the paper.

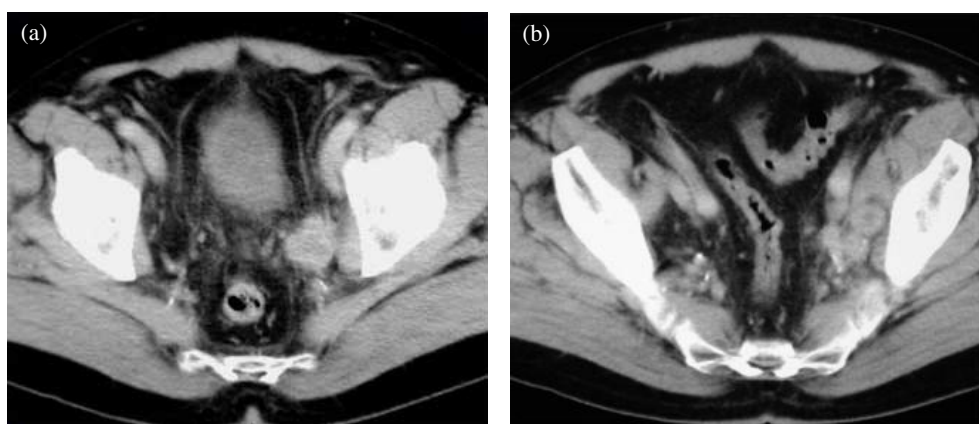


Figure 1 Prostate cancer. CT scan showing (a) left obturator nodal involvement and (b) left obturator and hypogastric nodal spread.

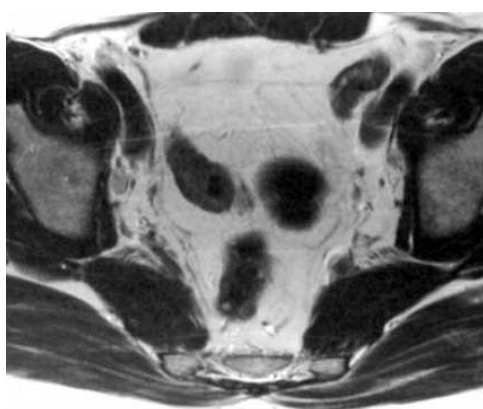


Figure 2 Prostate cancer. T2-weighted MR image showing a minimally enlarged lymph node in the right obturator group.

In 10–30% the lateral sacral/presacral nodes are the only sites of nodal disease; these nodes are not sampled at pelvic lymph node dissection (PLND) (Fig. 3).

Paraaortic nodes are involved late. They are often the only sites of nodal involvement at relapse following pelvic radiotherapy (Table 1)^[2].

Table 1 [3,4]

T stage	Incidence of nodal metastases (%)
Organ confined disease (T1/T2)	<5
Focal capsular penetration (Early T3)	15
Extracapsular spread (T3)	30
Advanced local disease (T4) e.g. seminal vesicle invasion	>40

At radical prostatectomy, 5–10% of cases have involved nodes^[5,6].

Survival depends on the number of positive nodes: 5-year disease-free survival-solitary nodal involvement 75–80%; multiple nodes 20–30%.

High-risk patients have a 50% chance of nodal involvement. There is also an increased risk in clinical stage T3 disease.

High and low-risk groups may be used to select patients for lymphadenectomy and for imaging.

High-risk PSA ≥ 20 ng ml⁻¹, Gleason score ≥ 7 ; Low-risk PSA < 20 ng ml⁻¹, Gleason score < 7 .

Bladder cancer

Bladder cancer spreads to the paravesical, lateral sacral and presacral nodes, then to the obturator, hypogastric, external iliac and common iliac nodes.

Obturator nodes are involved in 75% of those with nodal disease (Table 2)^[1].

Table 2 [7,8]

T stage	Incidence of nodal metastases (%)
Superficial tumours (T1)	<5
Superficial tumours (T2a)	10–15
Muscle invasion (T2b)	15–20
Extravesical spread (\geq T3a/b)	30–50
Adjacent organ invasion (T4)	40–45

Three-year survival with a solitary positive node is approximately 50%. Survival is reduced to approximately 25% if multiple nodes are involved. Node-negative patients have survival of approximately 70%^[9].

PLND is only beneficial in selected patients with metastases confined to one or few nodes, as most patients with nodal metastases already have systemic spread.

Colorectal cancer

A network of lymphatic vessels converge to form three major channels: (1) lymphatics draining the upper rectum above the peritoneal reflection drain into the inferior mesenteric nodes and then to the paraaortic

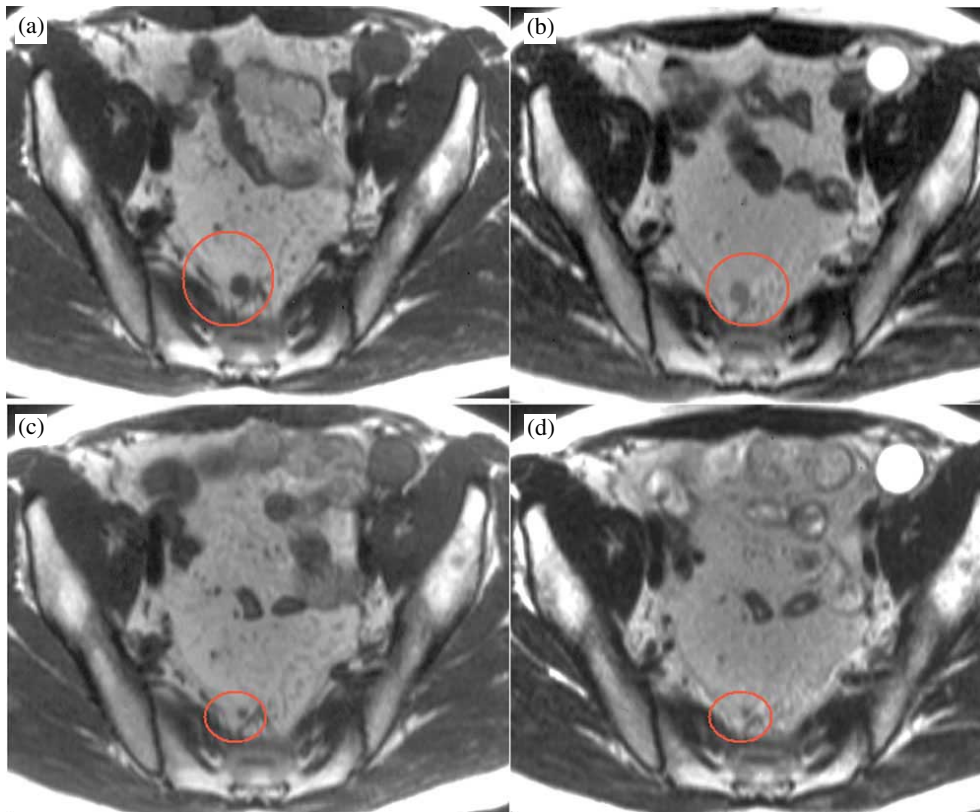


Figure 3 Prostate cancer. (a) & (b) T1 and T2-weighted images prior to radiotherapy showing a 1 cm presacral lymph node. (c) & (d) The same patient post-treatment. The lymph node has regressed considerably during treatment demonstrating response to radiotherapy.

nodes; (2) middle rectal lymphatics below the peritoneal reflection drain into the obturator and hypogastric nodes; (3) lower lymphatic vessels drain the lower rectum and spread is mainly to the inguinal nodes (Fig. 4) (Table 3).

Table 3 [10]

Tumour stage	Incidence of nodal metastases (%)
T1 (superficial into submucosa)	3–10
T2 (muscularis propria)	10–30
T3 (serosal invasion or invasion of perirectal fat)	>50

For lymph node-negative patients with T3 tumours, survival is approximately 70% compared with 35% if nodes are positive^[11,12].

Survival is significantly better for node-positive patients with 1–3 nodes involved compared with more than 3 nodes^[12].

Total mesorectal excision is increasingly practised for rectal cancer with significant reduction in mortality and recurrence rates^[13].

CT/MR findings of nodal involvement

Metastases from pelvic cancers frequently produce little, if any, nodal enlargement. Enlarged lymph nodes in the pelvis may be benign, due to reactive hyperplasia or inflammation. The criteria for assessment of nodal involvement include: (1) site; (2) size; (3) shape; (4) number of nodes; (5) nodal characteristics.

Site

The anatomical position of nodes in relation to the pattern of spread of the primary tumour is important (vide supra).

Size

Pelvic nodes greater than 8 mm in maximum short axis diameter (MSAD) should be regarded as enlarged on CT and MR^[14]. In two recent studies we have measured the normal MSAD of nodes in the pelvis on CT and MR (Table 4)^[15,16]. On MR a greater number of smaller nodes are identified.

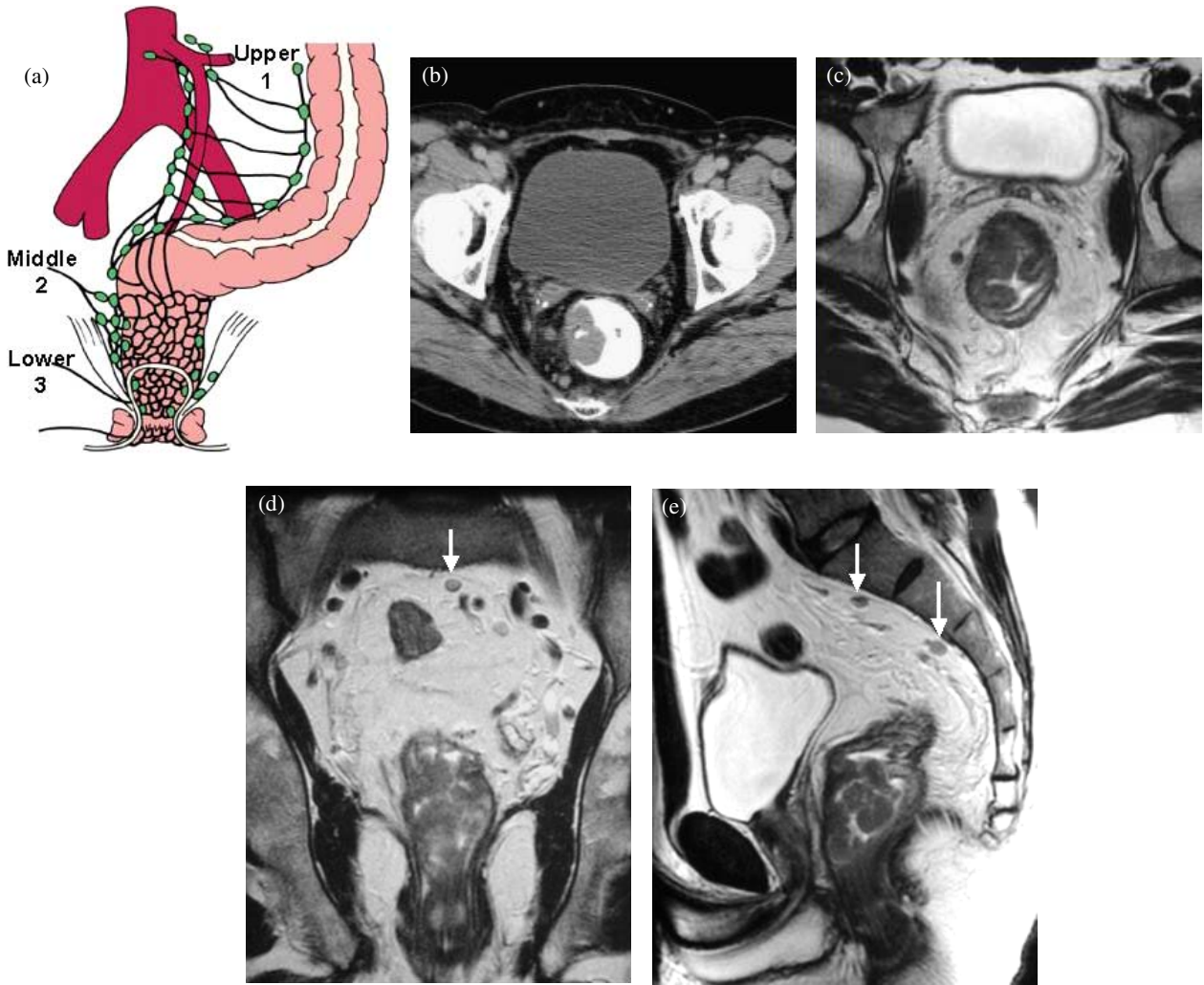


Figure 4 (a) Diagram demonstrating pathways of lymphatic spread in rectal cancer. (b) CT scan showing a T3 rectal cancer. Two pararectal lymph nodes (6 mm in diameter) are shown. (c) T2-weighted MR image also showing a T3 primary rectal cancer. Note: 6 mm pararectal lymph node on the right. (d) Coronal image in the same patient showing an 8 mm lymph node in the presacral space (arrow). (e) Sagittal MR image in the same patient showing the same presacral node (arrow) and another enlarged node inferior to this.

Table 4 [15,16] Normal lymph node size—MRI/CT 95th percentile value—5% FP rate

	MRI (mm)	CT (mm)
Common iliac	4	6.5
External iliac	5	6.0
Obturator	4	5.1
Internal iliac	5	4.0
Hypogastric	6	—

Shape

Round (spherical) nodes are more likely to be malignant than oval nodes according to several studies^[14]. Ill-defined and irregular shaped nodes are features suggestive of malignancy (Fig. 5).

Number of nodes

A cluster of normal nodes may suggest malignant involvement but asymmetry in the pelvis is common, making this sign less reliable^[17].

Nodal characteristics

CT findings

Pelvic nodal metastases usually have a soft tissue-density, but other features may be helpful in diagnosing metastatic involvement.

Calcification is typically seen in rectal and ovarian cancer.

A low-density central area of necrosis is seen in large nodes greater than 2–3 cm.

Low-density ‘cystic’ nodes are seen typically in testicular cancer.

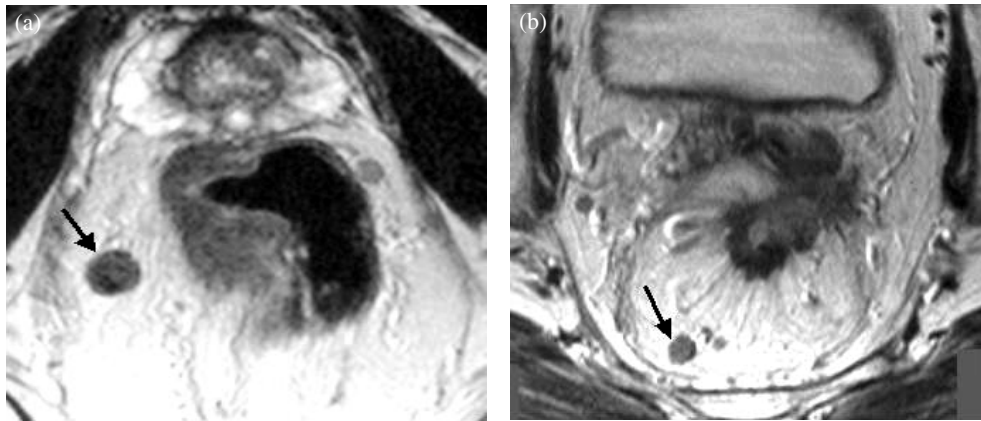


Figure 5 (a) and (b) Rectal cancer. Two patients with advanced disease showing enlarged ill-defined irregular lymph nodes. Note: both nodes (arrows) have a heterogeneous signal intensity on these T2-weighted images.

Nodes frequently enhance with intravenous contrast medium^[18]. If inhomogeneous enhancement of a large node is seen, this is more likely to be malignant, but homogeneous enhancement may be due to benign or malignant disease.

Avid enhancement suggests an aggressive tumour, a similar pattern often being seen in the primary tumour as well as in the lymph nodes.

Fatty infiltration indicates benign enlargement.

MR findings

T1-weighted images show nodes which have low signal intensity but which are usually a little higher than normal vessels.

T2-weighted images show intermediate signal intensity. High signal intensity on fast spin-echo imaging may obscure visualisation of nodes against pelvic fat.

Heterogeneous nodes of intermediate signal on T2-weighted images are more likely to be malignant than homogenous nodes (Fig. 5).

STIR sequence—high signal intensity is seen in enlarged lymph nodes and metastases cannot be distinguished from benign enlargement.

Tumours may enhance in a similar manner to CT.

Signal intensity time curves may be helpful for detecting nodal involvement in normal-sized nodes^[19].

Pitfalls in diagnosis

Normal structures and pelvic pathology can be misinterpreted as nodes. Common pitfalls include loops of bowel, normal ovaries, vessels and aneurysms, lymphocele, haematoma or abscess and nerves, e.g. the hypogastric plexus (Fig. 6).

These pitfalls are seen both with CT and MR. MR may be helpful in elucidating problems on CT and vice versa.

Accuracy of imaging and impact of positive and negative results on patient management

The overall accuracy of CT and MR imaging in detection of pelvic nodal disease is similar, with reported accuracies of between 75–100%. Sensitivities range from 48–87% and specificities from 64–100%^[20–24]. Low sensitivities are the main problem with both techniques due to the inability to identify nodal metastases in normal or only minimally enlarged nodes. A recent study comparing dynamic helical CT with dynamic MR in patients with cervical cancer showed sensitivities of 64.7 and 70% respectively; specificities were 96.6 and 89.8% respectively. Thus no significant difference in accuracies with the techniques was observed using modern up-to-date equipment^[25].

Interpretation and appropriate weighting should be given to the clinical importance of lymph node detection. For example in patients with prostate cancer being considered for pelvic lymphadenectomy, the diagnosis of metastatic nodal involvement may preclude surgery and thus the margin of error must be as small as possible. However, in patients to be treated with radiotherapy, the impact of a false-positive examination is less dramatic, potentially allowing a larger margin of error in lymph node detection.

As clinical practice develops, knowledge of nodal status may be important, not so much for determining whether or not to pursue a radical treatment approach, but rather in selecting different radical options, for example the type of surgery, the radiotherapy treatment volume or the need for adjuvant therapy. This approach is based on recent studies that have demonstrated that selected patients with nodal disease are curable. For example, the RTOG 75-06 study reported by Hanks *et al.*^[26] showed a 10-year cancer-free survival of 70% in node-positive patients and in another recent study of 790 patients with localised prostate cancer treated

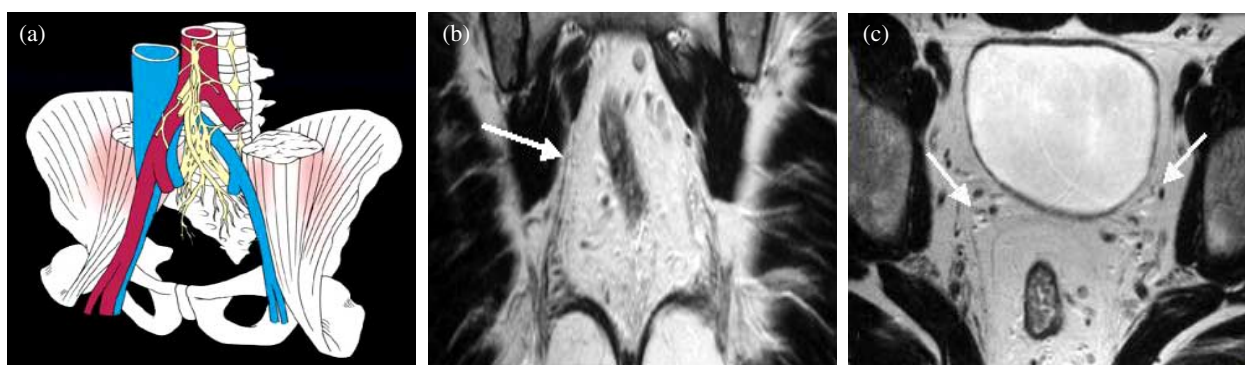


Figure 6 (a) Diagram showing the hypogastric nerve plexus. (b) Coronal image demonstrating the hypogastric plexus (arrow) on a T2-weighted MR sequence. (c) Axial image in the same patient demonstrating branches of the plexus (arrow) adjacent to vessels.

with radical prostatectomy, lymph node dissection and androgen deprivation, a 15-year disease specific survival of 60% in node-positive patients was demonstrated.

New developments and approaches to nodal staging

Reduction in size criteria

Oyen *et al.*^[24] showed a sensitivity of 78% and specificity of 97% in prostate cancer, using 6 mm as the upper limit of normal on CT. Fukuda *et al.*^[27] used 5 mm as the upper threshold (thin 3 mm sections) and showed accuracy, sensitivity, specificity and positive and negative predictive values of 79.4, 85.7, 77.8, 50.0 and 95.5% respectively on CT. Current evidence of normal-sized nodes on CT and MR [14,16] suggests that reduction in threshold to 6 mm MSAD as the upper limit of normal might improve sensitivity. However the use of such lower criteria also raises important practical issues related to radiologists' time and how best to deal with these minimally enlarged nodes in a given clinical scenario.

Increased specificity

Oyen *et al.*^[24] have shown improved specificity by obtaining cytology from suspicious nodes greater than 6 mm in diameter. In their series, specificity was improved from 96.6 to 100%.

Fast dynamic contrast-enhanced CT

Obtaining signal intensity semi-quantitative data of contrast enhancement characteristics may be helpful for distinguishing malignant from benign nodes^[19]. Quantitative measurements of capillary permeability of tumour and nodes may provide more accurate assessment.

MR-guided biopsy of pelvic nodes

This also feasible but not yet generally performed in routine clinical practice.

MR lymphography

MR lymphography using ultrasmall iron oxide particles (USIOP) already shows promise in identifying metastases in normal-sized nodes and will shortly be introduced into routine clinical practice^[28].

References

- [1] Golimbu M, Morales P, Al-Askari S *et al.* Extended pelvic lymphadenectomy for prostatic cancer. *J Urol* 1979; 121: 617–20.
- [2] Spencer J, Golding S. CT evaluation of lymph node status at presentation of prostatic carcinoma. *Br J Radiol* 1992; 65: 199–201.
- [3] Perrin P, Fendler JP, Devonec M. Is lymph node dissection still needed in radical prostatectomy? In: *Lymph Node Surgery in Urology*, International Society of Urology Reports Donohue JP, ed. Oxford: ISIS Medical Media, 1995: 86–90.
- [4] Neal AJ, Dearnaley DP. Prostate cancer: pelvic nodes revisited—sites, incidence and prospects for treatment with radiotherapy. *Clin Oncol* 1993; 5: 309–12.
- [5] Danella JF, de Kernion JB, Smith RB, Steckel J. The contemporary incidence of lymph node metastasis in prostate cancer: implications for laparoscopic lymph node dissection. *J Urol* 1993; 149: 1488–91.
- [6] Bundrick WS, Culkin DJ, Mata JA *et al.* Evaluation of the current incidence of nodal metastasis from prostate cancer. *J Surg Oncol* 1993; 52: 269–71.
- [7] Lerner SP, Skinner DG, Lieskovsky G *et al.* The rationale for en bloc pelvic lymph node dissection for bladder cancer patients with nodal metastases: long-term results. *J Urol* 1993; 149: 758–65.
- [8] Herr HW. Bladder cancer: pelvic lymphadenectomy revisited. *J Surg Oncol* 1988; 37: 242–5.
- [9] Blas Marin M, Rioja Sanz C, Rioja Sanz LA. Lymph nodes in bladder cancer. In: *Lymph Node Surgery in Urology*, International Society of Urology Reports Donohue JP, ed. Oxford: ISIS Medical Media, 1995: 37–42.
- [10] Graham RA, Gainsey L, Jessup JM. Local excision of rectal carcinoma. *Am J Surg* 1990; 160: 306–12.

- [11] Willet GG, Tepper JE, Cohen AM *et al.* Failure patterns following curative resection for colonic cancer. *Ann Surg* 1984; 200: 685.
- [12] Cohen AM, Tremmittera S, Candela F *et al.* Prognosis of node positive colon cancer. *Cancer* 1991; 67: 1859.
- [13] McAnena OJ, Heald RJ, Lockhart-Mummery HE. Operative and functional results of total mesorectal excision with ultra-low anterior resection in the management of carcinoma of the lower one-third of the rectum. *Surg Gynaecol Obstet* 1990; 170: 517–21.
- [14] Barentsz JO, Engelbrecht MRW, Witjes JAM *et al.* MR imaging of the male pelvis. *Eur Radiol* 1999; 9: 1722–36.
- [15] Vinnicombe S, Norman A, Husband J, Nicolson V. Normal pelvic lymph nodes: documentation by CT scanning after bipedal lymphangiography. *Radiology* 1995; 194: 349–55.
- [16] Grubnic S, Vinnicombe SJ, Norman A, Husband JE. MR evaluation of normal retroperitoneal and pelvic lymph nodes. *Clin Radiol* 2002; 57: 193–200.
- [17] Roy C, le Bras Y, Mangold L *et al.* Small pelvic lymph node metastases: evaluation with MR imaging. *Clin Radiol* 1997; 52: 437–440.
- [18] Husband JE, Robinson L, Thomas G. Contrast enhancing lymph nodes in bladder cancer. *Clin Radiol* 1992; 45: 395–8.
- [19] Barentsz JO, Jager GJ, van Vierzen P. Staging urinary bladder cancer after transurethral biopsy: the value of fast dynamic contrast-enhanced MR imaging. *Radiology* 1996; 201: 185–93.
- [20] Kim SH, Kim SC, Choi BI *et al.* Uterine cervical carcinoma: evaluation of pelvic lymph node metastasis with MR imaging. *Radiology* 1994; 190: 807–11.
- [21] Thurnher SA. MR imaging of pelvic masses in women: contrast-enhanced vs. unenhanced images. *Am J Roentgenol* 1992; 159: 1243–50.
- [22] Outwater E, Kressel HY. Evaluation of gynaecologic malignancy by magnetic resonance imaging. *Radiol Clin N Am* 1992; 30: 789–806.
- [23] Kim SH, Choi BI, Lee HP *et al.* Uterine cervical carcinoma: comparison of CT and MR findings. *Radiology* 1990; 175: 45–51.
- [24] Oyen RH, van Poppel HP, Ameije FE *et al.* Lymph node staging of localized prostatic carcinoma with CT and CT-guided fine-needle aspiration biopsy: prospective study of 285 patients. *Radiology* 1994; 190: 315–22.
- [25] Yang WT, Lam WWM, Yu MY *et al.* Comparison of dynamic helical CT and dynamic MR imaging in the evaluation of pelvic lymph nodes in cervical carcinoma. *Am J Roentgenol* 2000; 175: 759–66.
- [26] Hanks GE, Buzydlowski J, Sause WT *et al.* Ten-year outcomes for pathologic node-positive patients treated in RTOG 75-06. *Int J Radiat Oncol Biol Phys* 1998; 40: 765–8.
- [27] Fukuda H, Nakagawa T, Shibuya H. Metastases to pelvic lymph nodes from carcinoma in the pelvic cavity: diagnosis using thin-section CT. *Clin Radiol* 1999; 54: 237–42.
- [28] Weissleder R, Elizondo G, Wittenberg J *et al.* Ultrasmall superparamagnetic iron oxide: an intravenous contrast agent for assessing lymph nodes with MR imaging. *Radiology* 1990; 175: 494–8.