

## REVIEW

# Spinal and meningeal metastatic disease

D MacVicar

*The Royal Marsden NHS Trust, Sutton, Surrey, UK*

*Corresponding address: Dr D MacVicar, Royal Marsden Hospital, Downs Road, Sutton, Surrey, SM2 5PT, UK.*

*Tel: +44 (0)20 8661 3420. Fax: +44 (0)20 8661 3506. E-mail: david.macvicar@rmh.nthames.nhs.uk*

Date accepted for publication 15 September 2001

### Abstract

This contribution presents an approach to diagnosis in patients known to have malignant disease, who present with neurological symptoms and signs which may be a result of epidural spinal cord compression or intradural spinal disease.

### Introduction

Neurological complications in patients with known malignant disease appear to be increasing in frequency. It is possible that this is simply a result of more effective treatment resulting in prolonged survival, allowing more metastases to develop at all sites. Alternatively, it is possible that the central nervous system (CNS) acts a sanctuary site for malignant cells from common solid tumours<sup>[1]</sup>. The effects of metastatic disease on the CNS can be severely disabling. The brain and spinal cord are enclosed in bone and relatively small volume disease can have a disproportionately damaging effect. In addition, the CNS lacks lymphatics so that oedema and biological detritus are difficult to remove<sup>[1]</sup>. In the patient with known malignancy, there is a variety of mechanisms which can affect the CNS and neurological symptoms in the cancer patient can be complex. For these reasons, the approach to imaging differs in some ways from that used in the previously well patient presenting with an acute neurological emergency (although it may transpire that such an emergency is the first manifestation of disseminated malignancy).

The more frequent spinal manifestations of malignancies are discussed below.

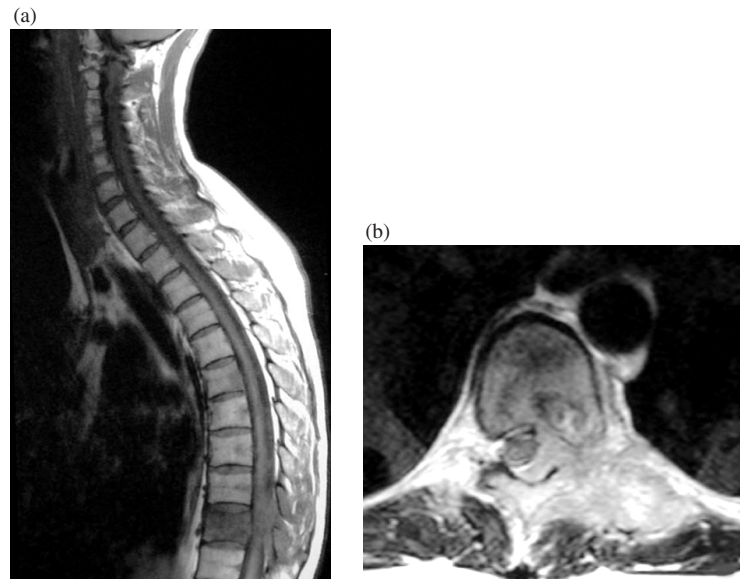
### Epidural spinal cord compression

Cord compression is most frequently a result of metastasis in the vertebral body. A soft tissue mass may also extend from the posterior elements of the vertebrae,

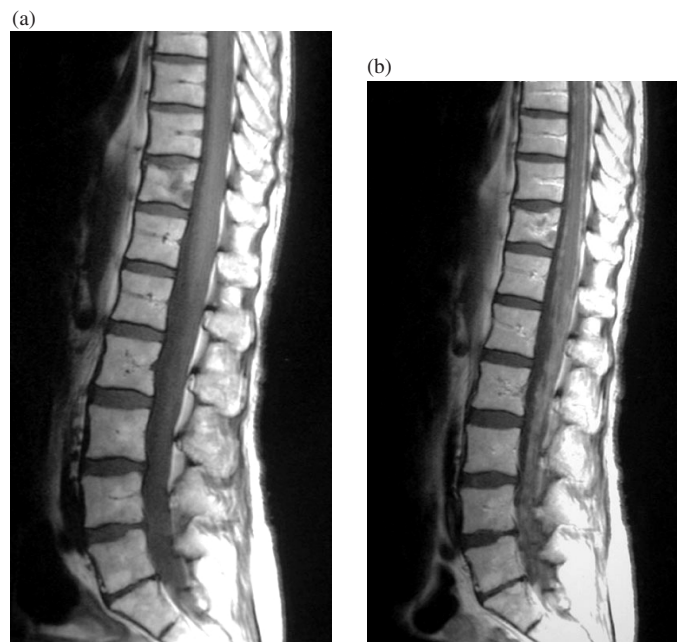
or from a paravertebral soft tissue mass invading through the neural foramen. The symptoms of cord compression in approximate order of frequency and importance are pain, power loss, sphincter disturbance and a sensory level. Pain is usually local or radicular, but may be funicular. Weakness begins in the legs regardless of the level of compression, and early in the development of symptoms is more marked proximally. Typical signs of upper motor neurone weakness, such as spasticity and hyper-reflexia, may be absent early in the clinical course<sup>[2,3]</sup>. In the patient with malignant disease, there may be more than one level, and compression of the lower motor neurones below the level of the conus may mask upper motor neurone signs from a cord compression more cranially. Sensory levels at the time of clinical presentation are frequently several segments below the actual level of compression.

For these reasons it is important to image the entire spine from sacrum to foramen magnum in all patients with suspected malignant cord compression<sup>[4–6]</sup>. MRI is the technique of choice, and sequence selection ideally includes sagittal T2-weighted and T1-weighted spin-echo sequences. If the patient is in pain and potentially unable to tolerate a full examination, the first manoeuvre should be to image the entire spine using the fastest reliable sequence. T1-weighted spin-echo imaging gives good contrast between tumour and normal bone marrow, and demonstrates the majority of epidural cord compressions. The second important principle is that any

This paper is available online at <http://www.cancerimaging.org>. In the event of a change in the URL address, please use the DOI provided to locate the paper.



**Figure 1** (a) Midline sagittal T1-weighted MRI shows a metastasis in the lower thoracic spine (T10). There is some epidural soft tissue, although this image does not confirm cord compression. Under these circumstances, orthogonal plane imaging should be undertaken. (b) Axial T2-weighted sequence shows epidural soft tissue disease extending from the posterior elements to the left of the midline. The cord is displaced to the right. The soft tissue component of disease frequently responds to radiotherapy, with resulting clinical improvement.



**Figure 2** (a) Sagittal T1-weighted image of lumbar region. The meninges show possible minimal thickening. (b) Gadolinium-enhanced sagittal T1-weighted image. Because the patient had diffuse back pain and mixed neurological signs, meningeal metastatic disease was suspected. Gadolinium-enhanced imaging demonstrates thickening and nodularity of the meninges in the lumbar region and around the distal cord (metastases from carcinoma of breast).

subtle abnormality detected on sagittal imaging should be interrogated with orthogonal plane imaging, which may demonstrate a soft tissue mass encroaching on the lateral aspects of the cord (Fig. 1). It is less important to interrogate obvious compressive lesions.

The blood supply of the spinal cord is also an important consideration. The anterior spinal artery is the main blood supply of the anterior part of the cord and runs in close proximity to the vertebral body. Anatomically unsuspectacular disease may cause the clinical syndrome

of cord compression by compromising the anterior spinal artery, resulting in infarction of the cord<sup>[2]</sup>.

### Meningeal metastatic disease

In the cancer patient, epidural cord compression by bony metastasis is the commonest myelopathic presentation. However, if the history is atypical and neurological signs do not fit with a discrete site of disease, meningeal metastatic disease should be considered. It is rarely the initial manifestation of metastatic disease, and may occur as a result of haematogenous spread, direct infiltration through neural foraminae (although the dura is relatively resistant to the passage of tumour), or as a result of drop metastases against a background of treated or untreated cerebral deposits. The most important aspect in diagnosis is to recognise the possibility clinically: the unenhanced T2 and T1-weighted sequences may be entirely normal or show subtle abnormalities. If the possibility is recognised, intravenous gadolinium is used to demonstrate the typical appearance<sup>[2,7]</sup>. Meningeal disease can be diagnosed with confidence if there are enhancing nodules or lumps (Fig. 2). Enhancement of the spinal meninges should always be considered abnormal, although linear enhancement is more difficult to interpret following lumbar puncture or therapeutic intervention such as brain surgery or radiotherapy. Sensitivity of gadolinium-enhanced MRI for detection of meningeal disease is far from 100%<sup>[8]</sup>, but is higher in detection of metastases from common solid tumours than in meningeal leukaemia or lymphoma. The commonest malignancies to metastasise to the meninges are leukaemia and lymphoma, breast, lung and melanoma<sup>[2]</sup>.

### Spinal cord deposits

As with meningeal metastatic disease, lesions in the cord itself may present with an atypical history and confusing neurological signs. Gadolinium enhancement is necessary to make the diagnosis with confidence<sup>[9]</sup>, and intra-axial deposits may be demonstrated when Gadolinium is given for suspected meningeal metastatic disease.

Once again, breast, lung and melanoma are among the commonest lesions to metastasise to the spinal cord.

### Key points

- (1) Neurological presentations are increasing in frequency and are clinically challenging problems in the cancer patient.
- (2) MRI is the investigation of choice for suspected epidural cord compression and should include the whole spine.
- (3) Craniospinal meningeal metastatic disease results in symptoms and signs which cannot be attributed to a single anatomical site.
- (4) Intra-axial spinal cord deposits may also present with atypical features, and both diagnoses are best made with gadolinium-enhanced T1-weighted imaging.

### References

- [1] Posner JB. Neurologic Complications of Cancer, Philadelphia: FA Davis Co., 1995.
- [2] MacVicar D. Metastatic effects on the nervous system. In: Imaging in Oncology. Husband JES, Reznick RH, eds. Oxford: ISIS Medical Media, 1998: 811–30.
- [3] MacVicar D. Neurological presentations in the cancer patient. *Imaging* 2000; 12: 115–29.
- [4] Cook AM, Lau TN, Tomlinson MJ *et al.* Magnetic resonance imaging of the whole spine in suspected malignant spinal cord compression: impact on management. *Clin Oncol* 1998; 10: 39–43.
- [5] Williams MP, Cherryman GR, Husband JE. Magnetic resonance imaging in suspected metastatic spinal cord compression. *Clin Radiol* 1989; 40: 286–90.
- [6] Loughrey GJ, Collins CD, Todd SM *et al.* Magnetic resonance imaging in management of suspected spinal canal disease in patients with a known malignancy. *Clin Radiol* 2000; 55: 849–55.
- [7] Collie DA, Brush Lammie GA *et al.* Imaging features of leptomeningeal metastases. *Clin Radiol* 1999; 54: 765–71.
- [8] Yousem DM, Patrone PM, Grossman RI. Leptomeningeal metastases: MR evaluation. *J Comput Assist Tomogr* 1990; 14: 255–61.
- [9] Crasto S, Ducas S, Davini O *et al.* MRI diagnosis of intramedullary metastases from extra-CNS tumours. *Eur Radiol* 1997; 7: 732–6.